

## **Clinical Case Study - March 2019**

### **Vertical sinus lift autograft and implant placement following regeneration with Bond Apatite®**

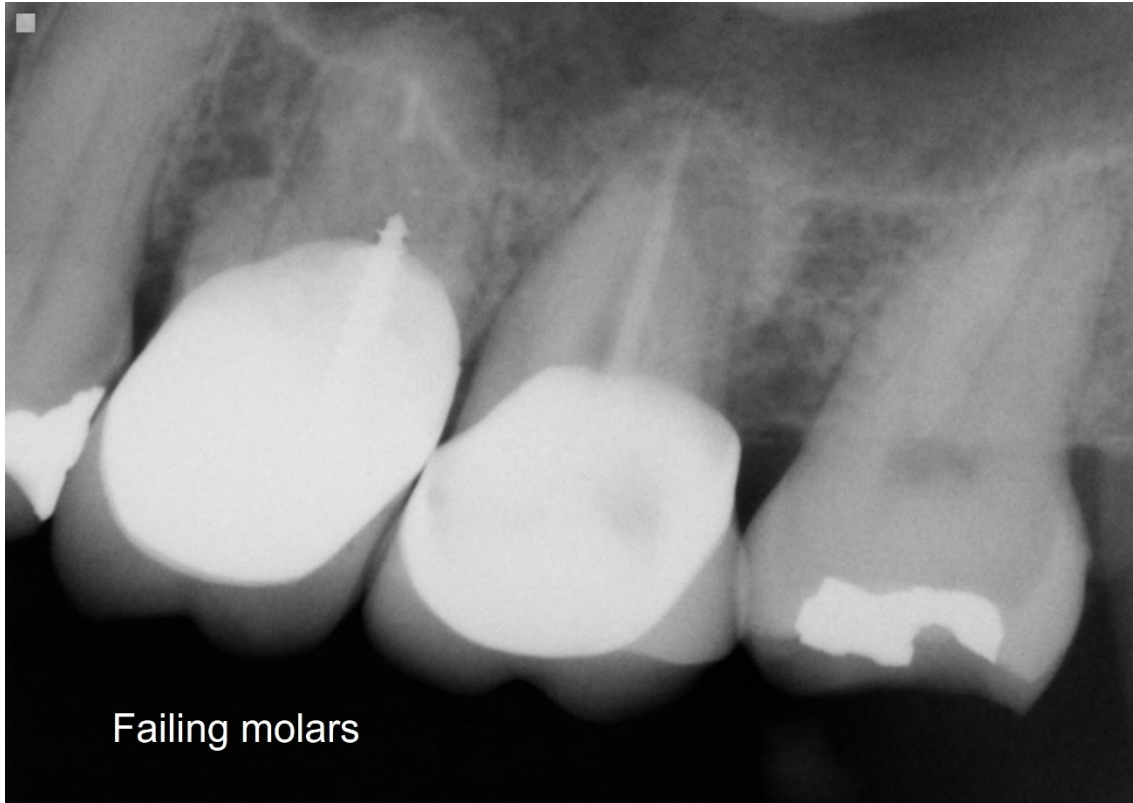*Surgery Michael Katzap DDS*

52-year-old female presented to treat two upper left failing molars. There was a buccal defect on the mesial buccal root of tooth number 14 and missing buccal bone.

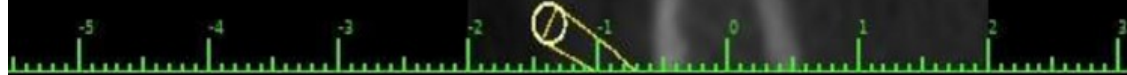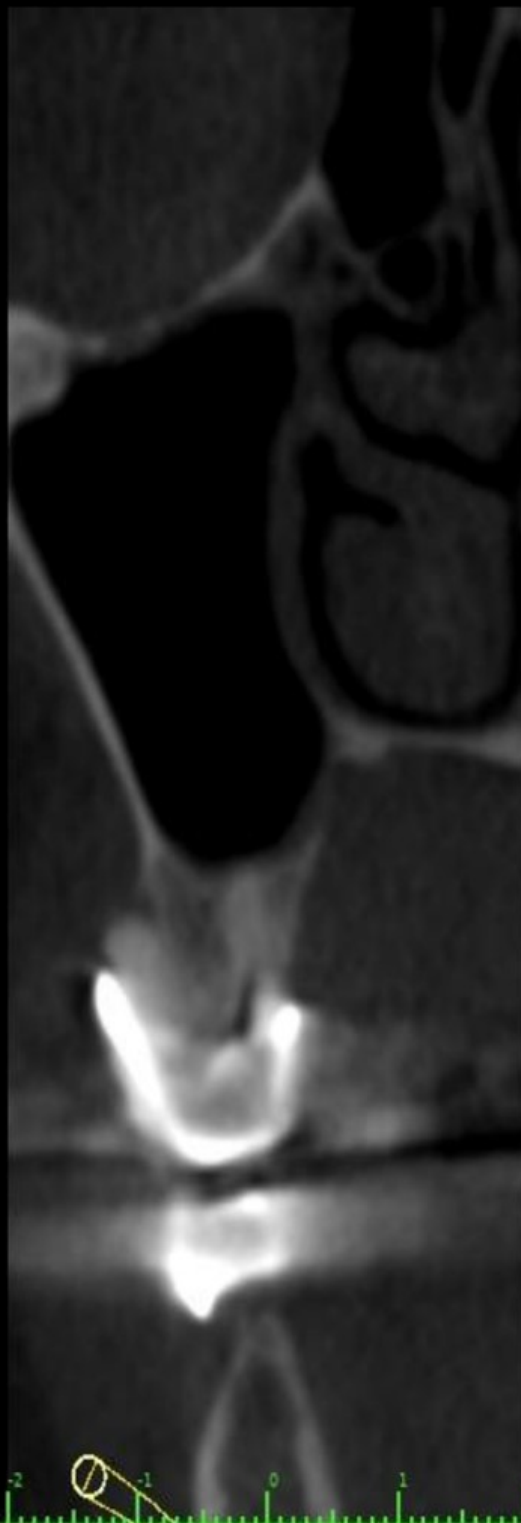
The teeth were extracted, the infection removed, the area was grafted with biphasic calcium sulfate cement (Bond Apatite). After four months of healing the area was reopened.

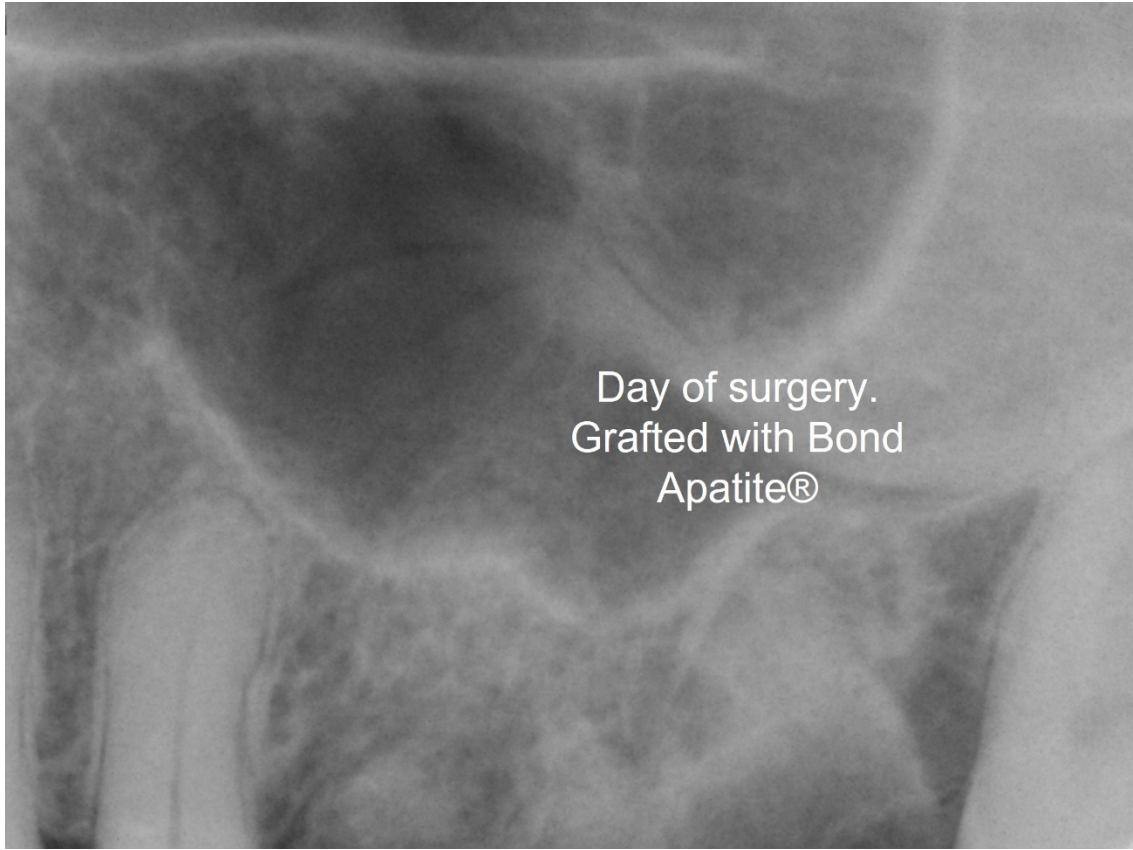
A vertical sinus lift was performed using densah burs using vertical lift protocol and autographed to allow placement of two implants.

---

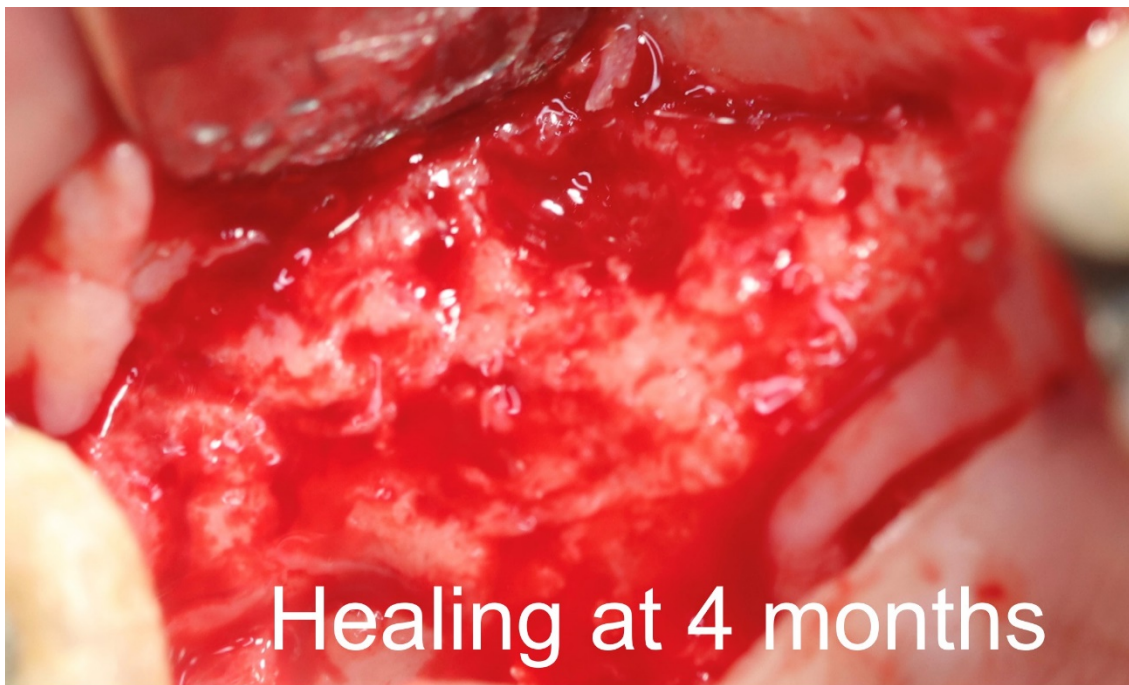
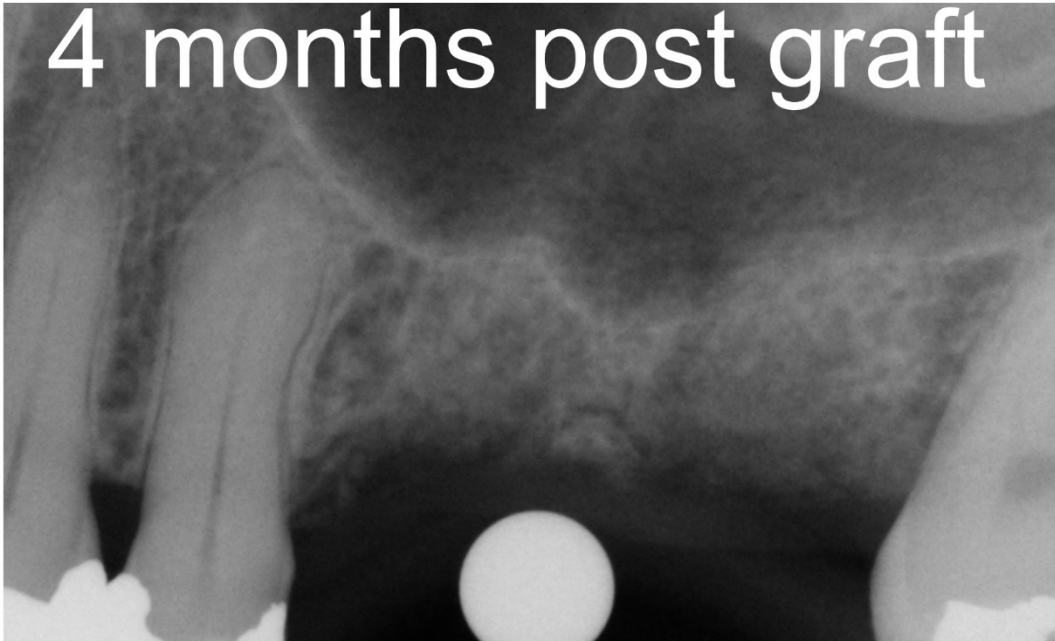
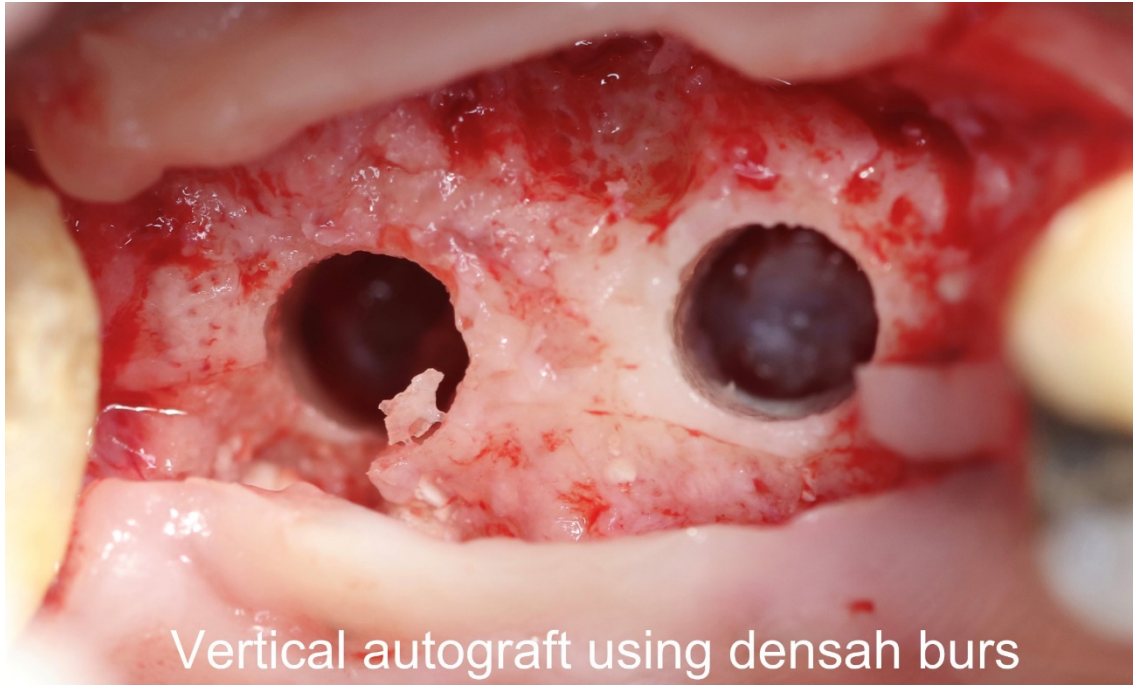
Note the MB root covered with PFM. No buccal plate





4 months post graft





Vertical autograft using densah burs

