

Atrophic ridge, Densah, Bond Apatite, scalloped gingiva

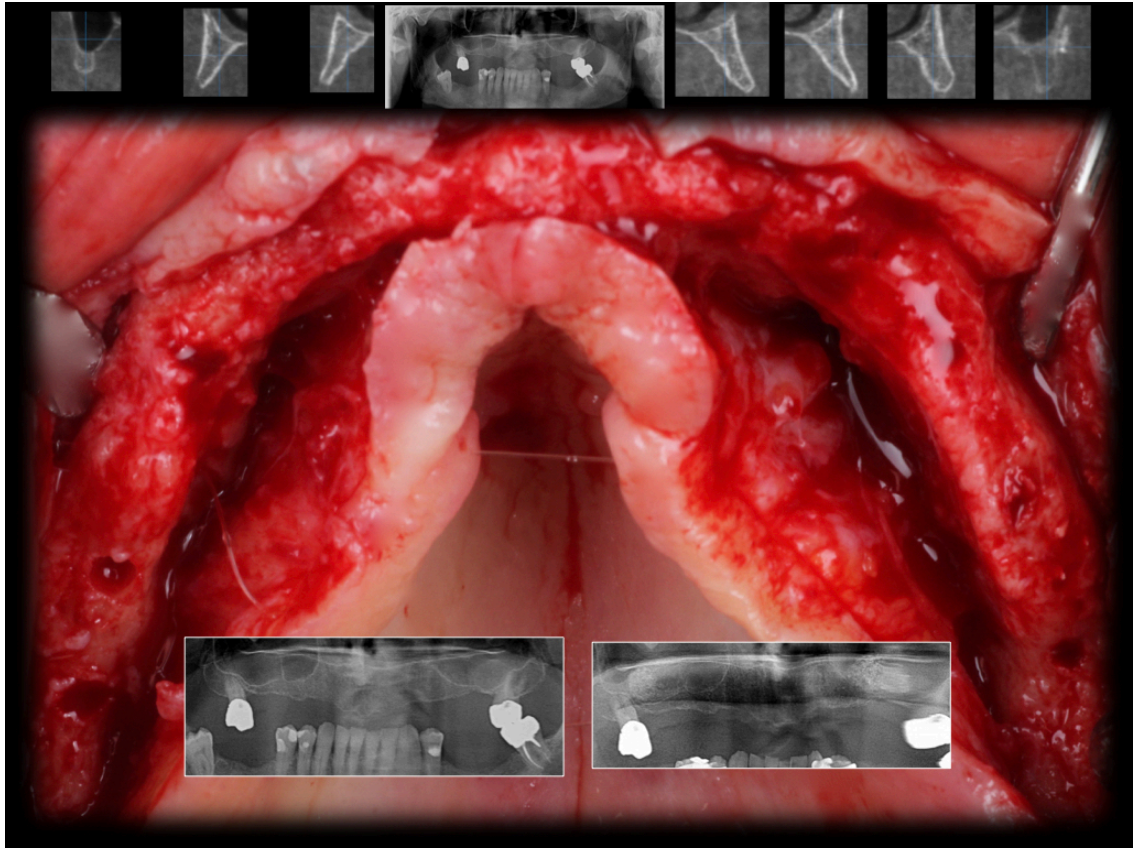
Surgery by: Dr. Snjezana Pohl

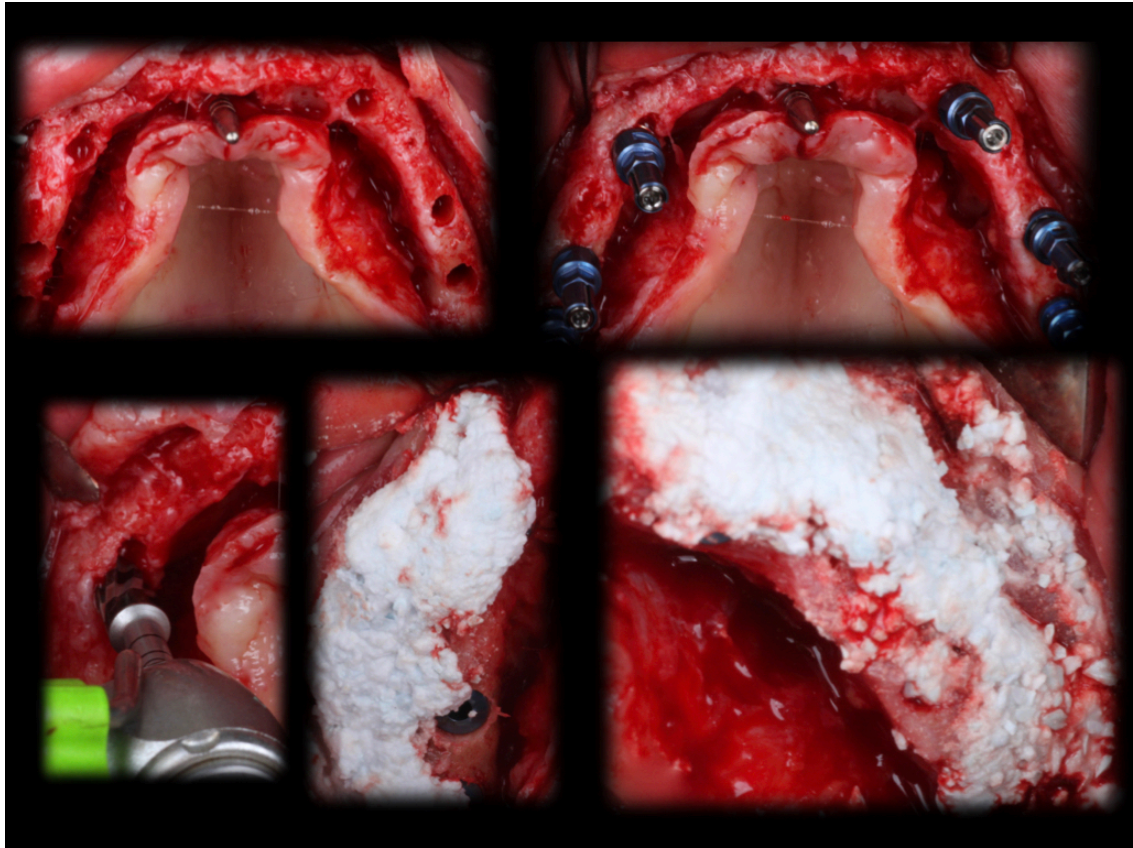
** This case was published on Dental Xp on Nov 4, 2018

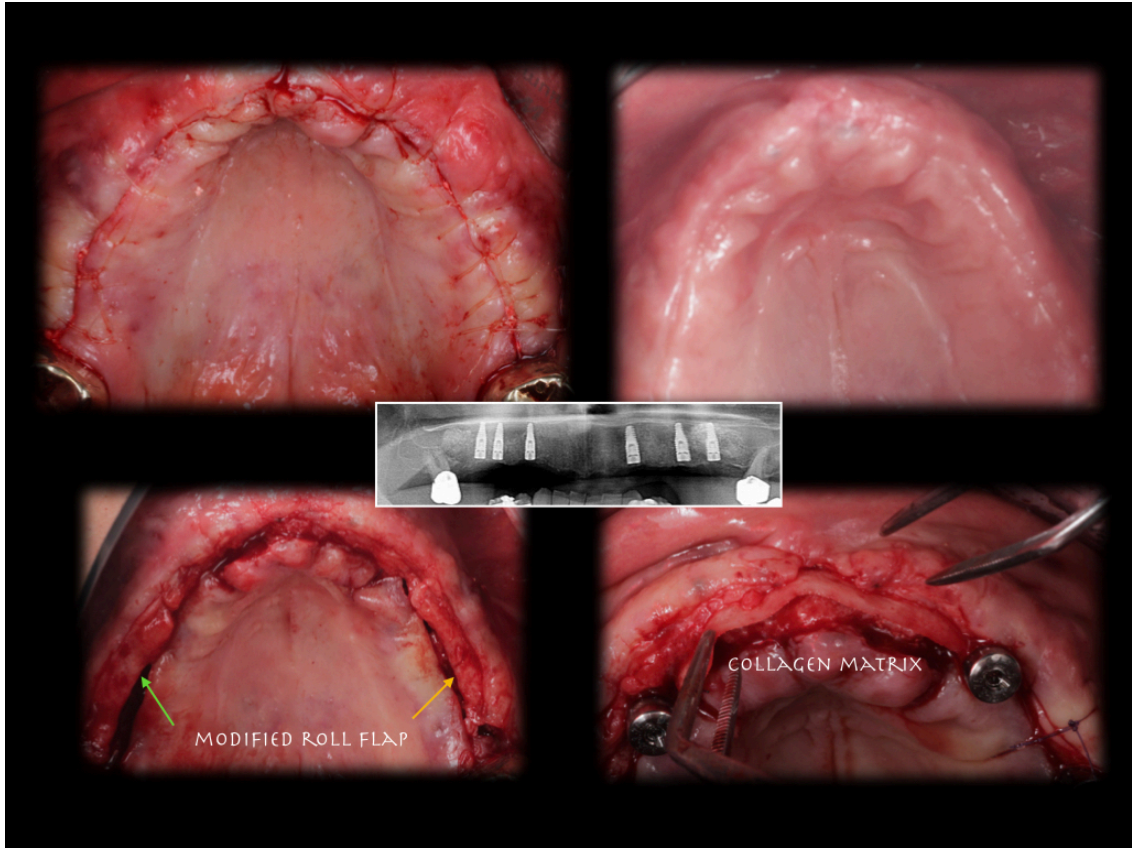
Layer by layer-as Salah Huwais described this case. Immediate loading was planned, for this reason, sinus elevation before implant placement. Unfortunately, two implants didn't have enough primary stability. OD made it possible to place implants inside the bone envelope. Thin ridge was augmented with bond apatite (major objection: it doesn't look good in images:). After three months implants were uncovered utilizing roll flap in lateral areas. In the anterior area collagen matrix and buccal sliding palatal pedicle flap. I am pleased with cleansable scalloped gingiva.

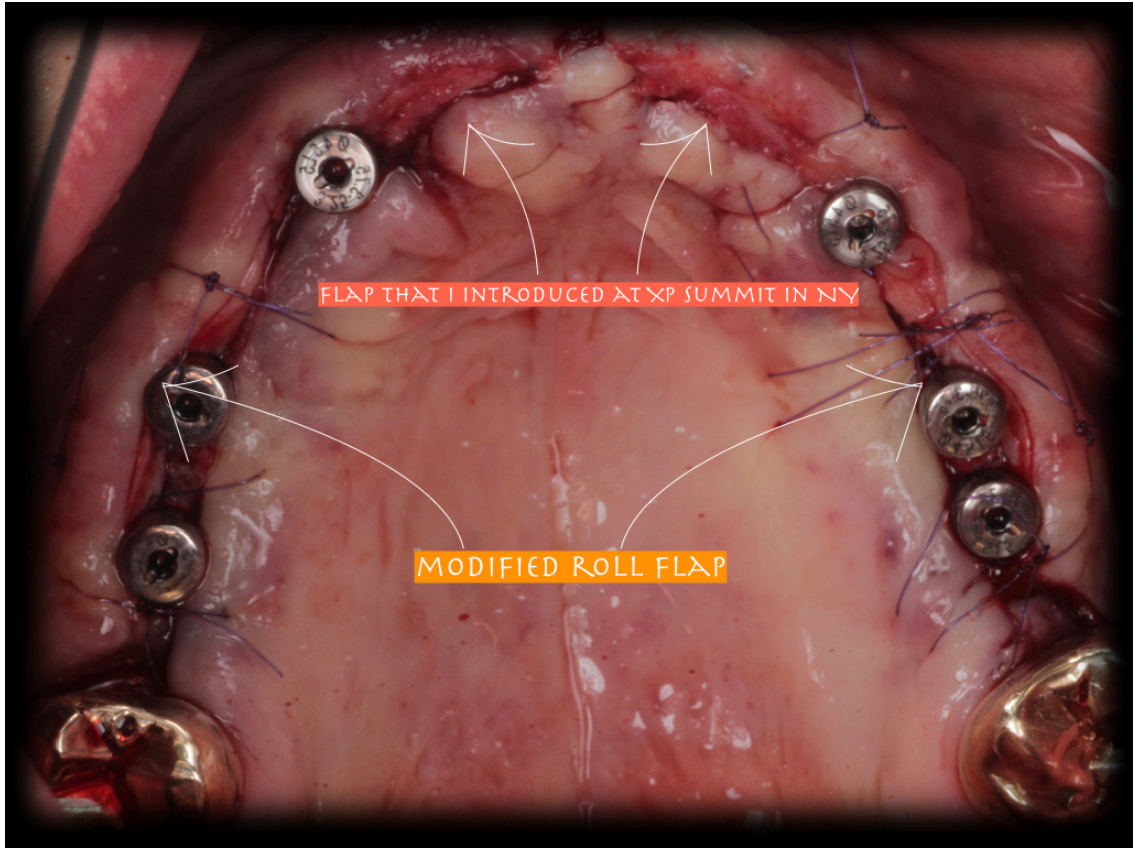
Occlusion line is not ideal - patient is saving money for the low jaw, it will take some time and prostho had to adjust the upper teeth to the low jaw situation.

* For the full case discussion: [Click here](#)









FLAP THAT I INTRODUCED AT XP SUMMIT IN NY

MODIFIED ROLL FLAP



