
Clinical Case Study - June 2019

Sinus augmentation and implants placement using Augma Bond Apatite® bone cement

Surgery by Stephane Berg, DDS

63 years old female, presented for fixed restoration of the missing upper right molars.

The molars were extracted 3 years earlier. The patient requested a fixed restoration. During case evaluation and treatment plan, because of the massive lack of bone, we decided to propose a 2 steps treatment. First, perform the sinus lift augmentation procedure and at the second stage to place the implants.

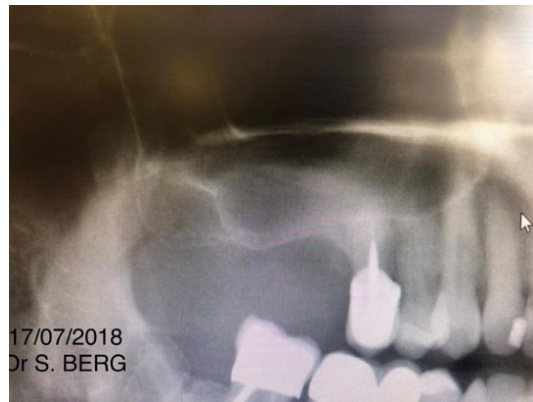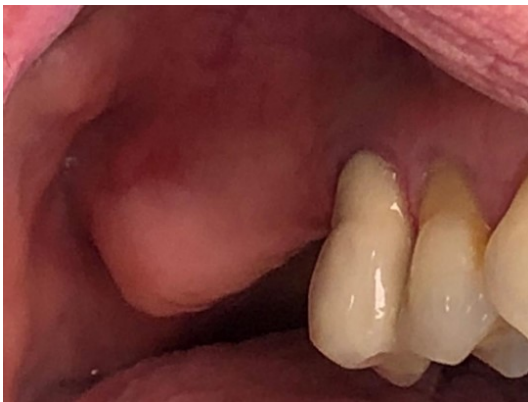1. Open sinus lift with lateral window approach was performed in July 2018 using biphasic calcium sulfate cement (Bond Apatite® Augma biomaterials Ltd.); the sinus cavity fill and the access window were closed by using bone apatite only, according to a

bone cements protocols. Flap closure with tension and no collagen membrane.

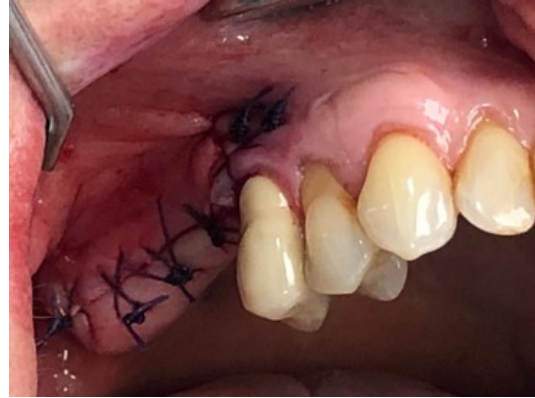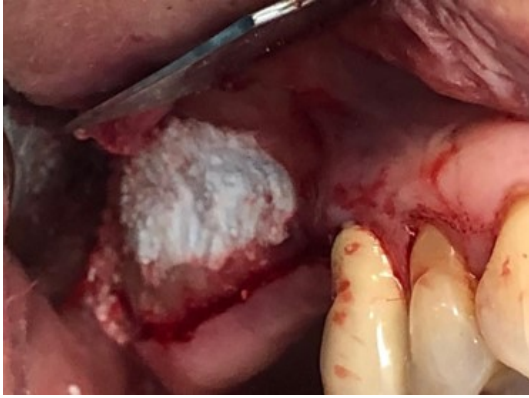
2.Implants surgery:

The CBCT demonstrated the perfect augmentation height and complete closure of the access window which allowed the placement of 2 implants.

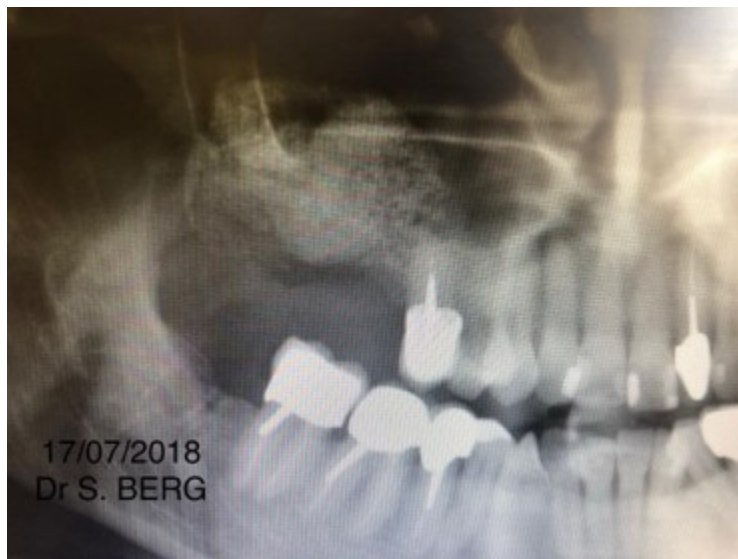The implants surgery was performed in March 2019 (Surcam, S-type).



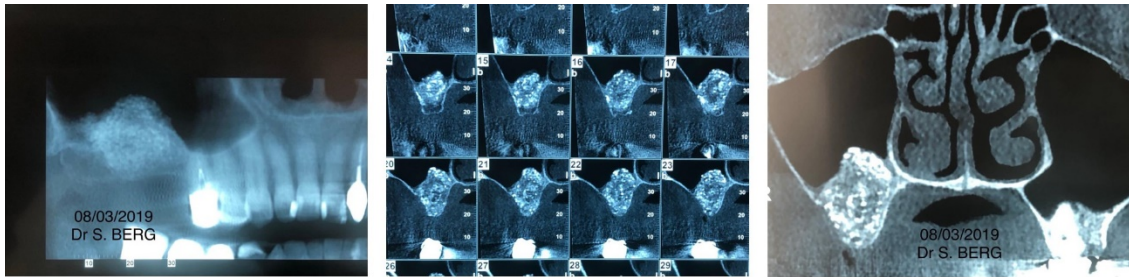
Clinical and radiographic appearance before sinus lift procedure



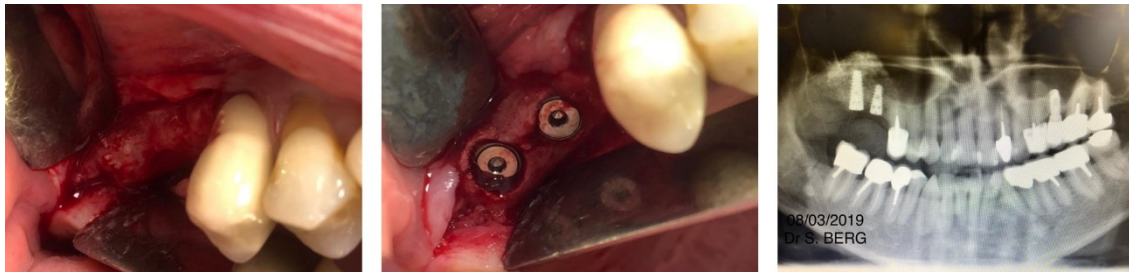
Open window sinus lift using
Bond Apatite®



Radiographic appearance after placement of Bond Apatite®



Radiographic appearance 8 months post op



Reentry and implants placement 8 months post op
